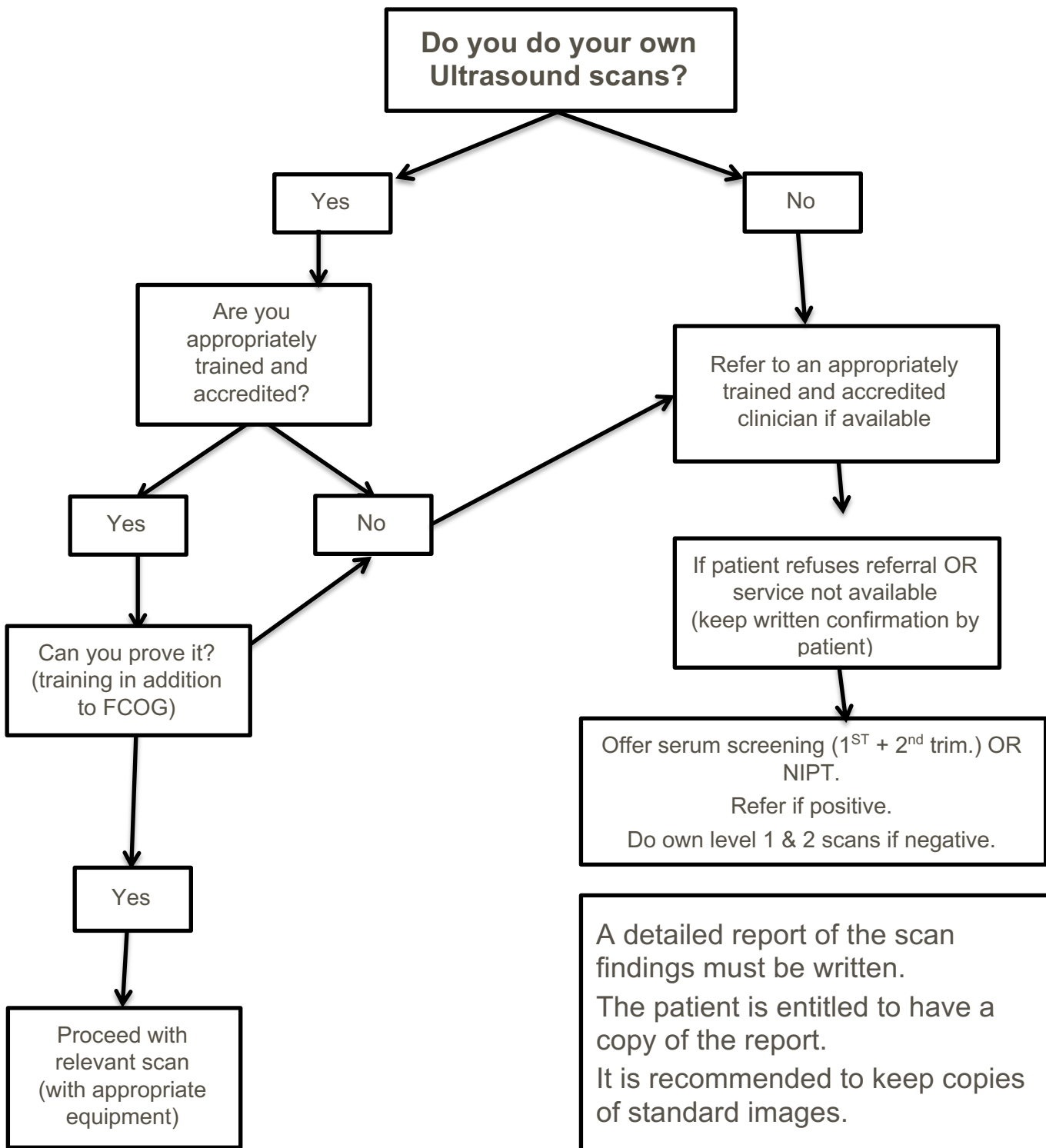




ULTRASONOGRAPHY SCREENING IN PREGNANCY 2.0



Required Level of skill

Level 1 – Basic Obstetric Scan
Level 2 – Basic Anatomy Survey
Level 3 – Advanced Fetal Scan

Appropriate Equipment

1. Good resolution
2. Ability to adequately enlarge the image
3. Callipers must measure in 0.1mm steps
4. Appropriate obstetric transducers with multiple frequencies (2 – 5 MHz)
5. Good colour and Doppler

Recommended Scans for Fetal anomalies

* 11 – 13⁶ weeks:

^ Down syndrome screening and some anomalies (minimum Level 2, preferred Level 3)

^ Preeclampsia screening (Accredited with FMF (UK) for uterine artery Doppler)

* NT Scan: Accreditation with FMF (UK)

* 18 – 22 weeks: Detailed anatomical scan (Level 3)

SASUOG recommendation for different scanning levels, depending on skills

1) The Basic Obstetric Scan (Level 1):

- In/Extra-uterine
- Cardiac activity
- Number of fetuses
- Placental localization (criteria gestation dependent)
- Fetal Presentation
- Biometry for dating and assessment of growth (CRL, BPD, AC, FL)
- Liquor volume

2) The Basic Anatomy Survey (Level 2):

- ALL OF THE ABOVE AND
- Normal appearance of biometry sections AND
- Head: shape, integrity
- Brain: Measure TCD (trans-cerebellar diameter), Atrium width – posterior horns of the lateral cerebral ventricles, normal appearance of posterior fossa and falx
- Nuchal fold thickness, no masses
- Face: 2 eyes with lens, nasal bone present, normal profile, upper lip intact
- Spine: Spine closed
- Thorax: Lungs present, no effusions or masses, diaphragm intact, ribs normal

- Heart: 4 chamber heart view, outflow tracts, 3 vessel view
- Abdominal Wall: Cord insertion
- GIT: Stomach present and left sided, no ascites, no dilated or hyperechoic bowel
- Bladder: Present
- Kidneys: 2 kidneys present and normal
- Limbs: Hands and feet present and in normal orientation
- Skeleton: 12 long bones
- Three vessel cord
- Placental masses
- Twin: chorionicity

If unable to confirm normal appearance of these views, the patient should be informed of the limitations of the scan, and a repeat scan or referral should be offered.

Any deviation from normal detected at this scanning level should be referred for second opinion. AFP screening should be offered as additional screening for neural tube defects.

3) Advanced fetal detailed scan (Level 3):

- ALL OF THE ABOVE AND
- Brain: corpus callosum and vermis normal in size and appearance
- Face: orbits position and size, lenses, lips and palate (alveolar ridge) intact, facial profile, nasal bone length, prenasal thickness
- Spine: Spine closed, vertebrae normal
- Thorax: Lungs present and normal, ribcage normal, diaphragm intact, no mediastinal shift
- Heart: 4 chamber heart view, outflow tracts, 3-vessel-trachea view including ARSA
- GIT: Stomach present and left sided, no ascites, no dilated or hyperechoic bowel, normal left umbilical vein
- Bladder: Present, size and shape normal
- Kidneys: 2 kidneys present and normal, measure pelvis if prominent
- Limbs: 12 long bones of normal shape and length, hands and feet present, normal orientation, fingers and toes intact
- Fetal sex
- Soft markers for aneuploidy, including ARSA and Nuchal Translucency (NT accreditation: FMF)
- Cervical length (TVS)
- Doppler studies
- Invasive procedures

References

1. ISUOG Practice Guidelines: Performance of first-trimester fetal ultrasound scan. ISUOG Clinical Standards Committee. *Ultrasound Obstet Gynecol* 2013; 41: 102–113. DOI: 10.1002/uog.12342
isuog.org GUIDELINES
2. ISUOG Practice Guidelines (updated): performance of the routine mid-trimester fetal ultrasound scan. L. J. SALOMON, Z. ALFIREVIC, V. BERGHELLA, C.M. BILARDO, G.E. CHALOUHI, F. Da Silva COSTA, E. HERNANDEZ-ANDRADE, G. MALINGER, H. MUNOZ, D. PALADINI, F. PREFUMO, A. SOTIRIADES, A. TOI and W. LEE on behalf of the ISUOG Clinical Standards Committee. *Ultrasound Obstet Gynecol* (2022). DOI: 10.1002/uog.24888

Authorship

These guidelines were drafted by a clinical team from Mediclinic and were reviewed by a panel of experts from SASOG and the BetterObs clinical team in 2019 and revised by the scientific subcommittee of BetterObs in 2022. All attempts were made to ensure that the guidance provided is clinically safe, locally relevant and in line with current global and South African best practice. Succinctness was considered more important than comprehensiveness.

All guidelines must be used in conjunction with clinical evaluation and judgement; care must be individualised when appropriate. The writing team, reviewers and SASOG do not accept accountability for any untoward clinical, financial or other outcome related to the use of these documents. Comments are welcome and will be used at the time of next review.

Released on 2022 08 01